Splenic Artery Embolization: A Non-Invasive Intervention for Blunt Splenic Injury

PRISMA HEALTH

School of Medicine Greenville

Prescott M[1]; Eager R[1]; Corso O[2]; Self S[3]; Cull J[4]; Schammel CMG[1,2]; Devane AM[1,5]

[1]University of South Carolina School of Medicine Greenville; [2]Pathology Associates; [3]Department of Epidemiology, Arnold School of Public Health, University of South Carolina, Greenville SC; [4]Department of Surgery, Prisma Health Upstate, Greenville SC; [5]Department of Radiology, Prisma Health Upstate, Greenville SC

Background

- Treatment for blunt splenic injury (BSI) was splenectomy, but asplenic patients have a life-time risk of developing overwhelming post-splenectomy infection (OPSI) which has a mortality rate for 33%.
- Non-operative management (NOM) foregoes surgical intervention to preserve the spleen by monitoring patients for signs of hemorrhage that require urgent surgical intervention.
- NOM with observation alone fails in up to 34% of cases.
- Splenic artery embolization (SAE) is a minimally invasive endovascular technique to reduce blood flow proximally (proximal SAE), distally (distal SAE), or both proximally and distally (combined SAE).
- The incorporation of SAE into NOM increases success rates to 86-100% while still preserving the immunologic function of the spleen. But it is still unclear whether proximal, distal, or combined SAE is the best approach.
- Candidates for SAE were limited to hemodynamically stable, young, patients with lower grade BSI, but recent studies suggest SAE should not be limited to this population.

Methods

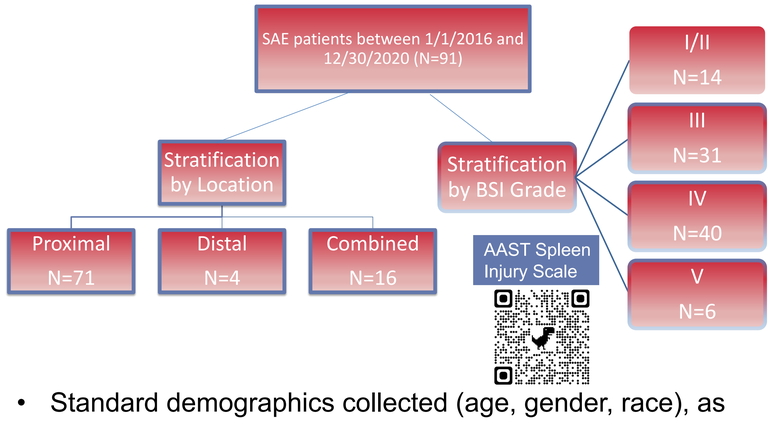

- Standard demographics collected (age, gender, race), as well as relevant history and results (MOI, hemodynamic status, CT findings).
- Patients clinicopathologic data (major and minor complications) during admission and at follow up 30 days post-discharge.

Embolization technique

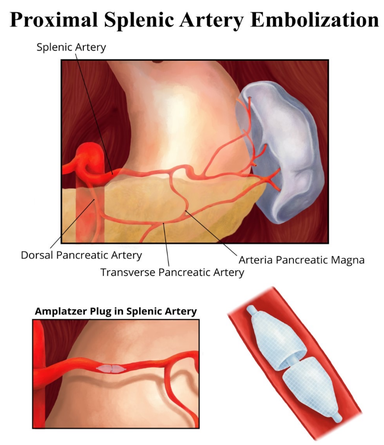

Figure 1

Proximal SAE is performed within the splenic artery between the origin of the dorsal pancreatic artery and the arteria pancreatic magna; this reduces arterial pressure to the spleen and maintains collateral circulation (pictured). Distal SAE occludes distal vessels within the splenic parenchyma and does not allow collateral flow from these vessels. A combination of these techniques can be used.

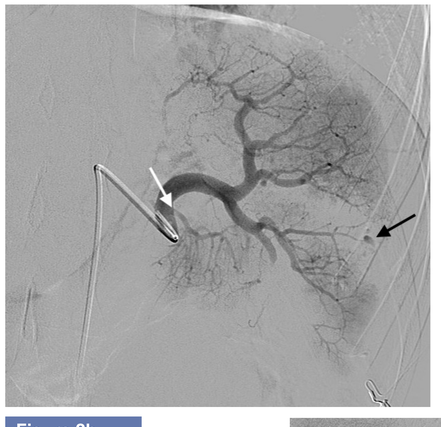

Figure 2a

Selective angiogram of the splenic artery demonstrates active arterial extravasation from the mid to inferior spleen (black arrow). Note the position of the pancreatic arteria magna (white arrow).

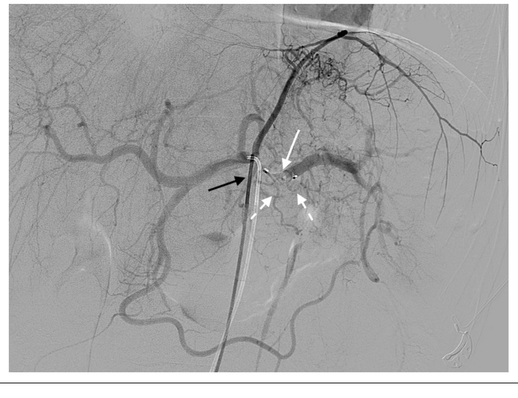

Figure 2b

Celiac angiogram post embolization of the proximal splenic artery with an Amplatzer plug (white arrow). The plug is located distal to the dorsal pancreatic artery (black arrow). Patent branches of the pancreatic arteria magna are labelled with broken white arrows. The splenic artery distal to the plug remains patent due to collateral vessels.

Aims

- To retrospectively compare outcomes of patients with BSI that underwent proximal, distal, or combined SAE and to assess whether patient demographics and clinical status impacted clinical success.

Results and Discussion

- SAE proved a 100% success rate and a 94.5% primary clinical success rate
- The major complication rate was 6.6%, with interventions for these including splenectomy (2.2%), re-embolization (1.1%), and abscess drainage (2.2%) and the minor complication rate was 23.1% with no significant difference between embolization location or BSI grade cohorts
- There was a significant difference in the type of vascular injury with active extravasation of contrast being the most common (n=50), pseudoaneurysm (n=24), and AV fistula (n=2), but there was no difference in complication rates by vascular injury type.
- By grade of injury, there was no significant difference in transfusion requirement, major or minor complications, or minor complications, but the high-grade injury group was significantly younger.

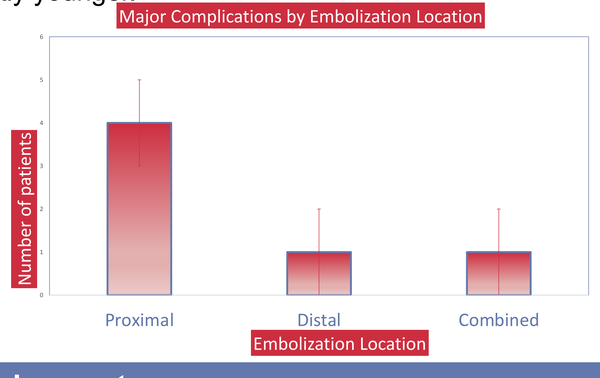

Acknowledgements

- Special thanks to my faculty advisors Dr. Christine Schammel and Dr. Michael Devane and to Olivia Corso who provided the illustrations for this poster.

Selected References

Lee R, Jeon CH, Kim CW, Kwon H, Kim JH, Kim H, et al. Clinical Results of Distal Embolization in Grade V Splenic Injury: Four-Year Experience from a Single Regional Trauma Center. J Vasc Interv Radiol. 2020;31(10):1570-7 e2.
Van der Vlies CH, van Delden OM, Punt BL, Ponsen KJ, Reekers JA, Goslings JC. Literature review of the role of ultrasound, computed tomography, and transcatheter arterial embolization for the treatment of traumatic splenic injuries. Cardiovasc Intervent Radiol. 2010;33(6):1079-87.
Miller PR, Chang MC, Hoth JJ, Mowery NT, Hildreth AN, Martin RS, Holmes JH, Meredith JW, Requarth JA. Prospective trial of angiography and embolization for all grade III to V blunt splenic injuries: nonoperative management success rate is significantly improved. J Am Coll Surg. 2014;218(4):644.
AAST Spleen Injury Grading Scale: https://www.aast.org/resources-detail/injury-scoring-scale#spleen

Contact: meaganp@email.sc.edu